

Acute gastritis and functional gastroparesis due to *Sarcina ventriculi* infection

Ted Xiao MD¹, Steven Delany MD²

¹Department of Internal Medicine, Wake Forest University School of Medicine, Winston-Salem, NC

²Department of Internal Medicine, Section of Gastroenterology, Wake Forest University School of Medicine, Winston-Salem, NC

INTRODUCTION

- *Sarcina ventriculi* is a rare anaerobic gram-positive coccus that grows in the stomach
- Prior cases linked to gastritis/ulceration, delayed gastric emptying, gastric outlet obstruction, and gastric perforation
- No established treatment
- We present a case of successfully treated *Sarcina ventriculi*-related GI dysfunctions

CASE DESCRIPTION

Patient is an 89-year-old male hospitalized for community-acquired pneumonia. He denied bowel movement and developed episodes of large volume, brown emesis on day 8. There was significant abdominal distention but no tenderness.

Abdominal radiography showed no acute obstruction but extensive gaseous distention of the stomach with moderate colonic stool burden (Fig 1). Gastroenterology was consulted. Nasogastric tube placement resulted in immediate improvement, but symptoms returned after 7 days.

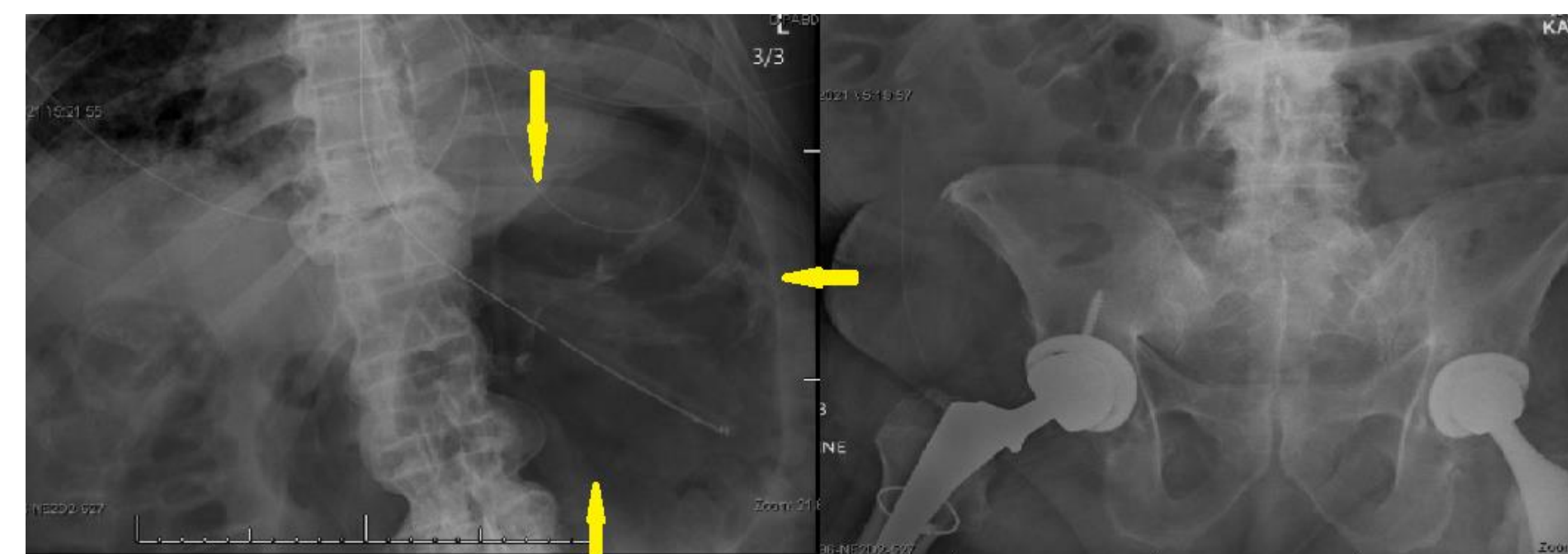


Figure 1. Abdominal radiography demonstrated no obstruction. Yellow arrows mark gastric distension.

An EGD found >500 cc retained fluid in the stomach and erythema with focal ulceration in the fundus (Fig 2A). Biopsy showed marked active gastritis with ulceration, fibrinous purulent exudate, and hemorrhage. *Helicobacter pylori* was negative but *Sarcina ventriculi* was identified.

Patient was started on ciprofloxacin 250mg twice daily and metronidazole 250mg three times daily for a 7-day course, and pantoprazole 40mg twice daily for 8 weeks. He had symptomatic improvement and was discharged.

He returned 4 months following discharge without symptoms of nausea or abdominal distention. Repeat CT abdomen showed mild thickening of the gastric wall which was later confirmed on EGD as normal mucosa (Fig 2B).

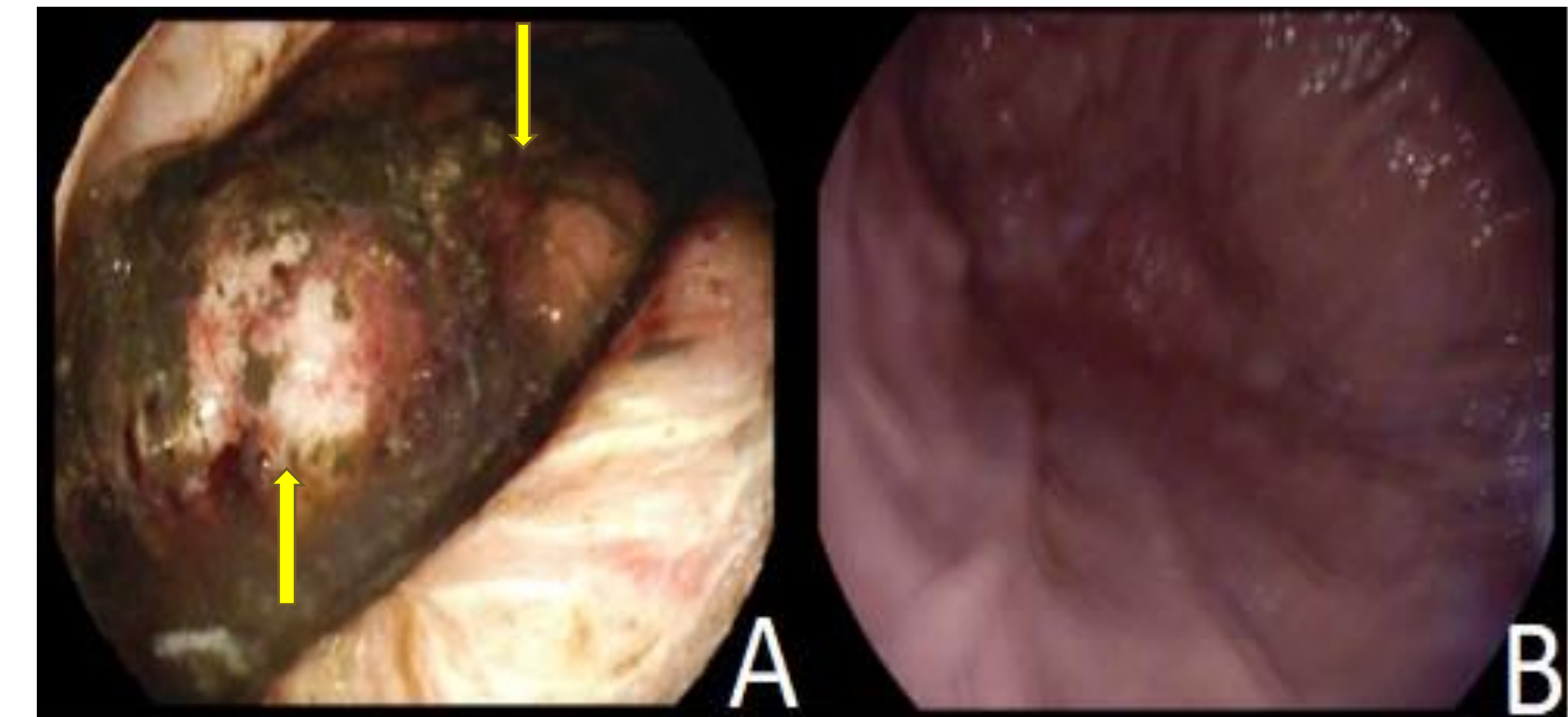


Figure 2. Endoscopic findings of gastritis, hemorrhage, and focal ulceration prior to treatment (A), and complete normal mucosa 4 months post treatment (B).

DISCUSSION

- *Sarcina ventriculi* infection causes emphysematous gastritis, ulceration, obstruction, and perforation
- Patient developed acute gastritis & functional gastric outlet obstruction with biopsy-confirmed *Sarcina ventriculi*
- Previous cases reported varying results with metronidazole and a fluoroquinolone
- Complete resolution of disease presentation after a 7-day course of ciprofloxacin and metronidazole with 8 weeks of PPI

REFERENCES

1. Marcelino LP, Valentini DF, Machado S, Schaefer PG, Rivero RC, Osvaldt AB. *Sarcina ventriculi* a rare pathogen. *Autops Case Rep.* 2021;11:e2021337. doi:10.4322/acr.2021.337
2. Hillman L, Jeans P, Whiting P. Gastrointestinal: *Sarcina ventriculi* complicating gastric stasis. *J Gastroenterol Hepatol.* Apr 2020;35(4):527. doi:10.1111/jgh.14892
3. Singh K. Emphysematous Gastritis Associated with *Sarcina ventriculi*. *Case Rep Gastroenterol.* Jan-Apr 2019;13(1):207-213. doi:10.1159/000499446