

Lower extremity muscle fat fraction is associated with motor performance in females with myotonic dystrophy type 2

Myotonic dystrophy type 2 (DM2) is a dominantly inherited muscular dystrophy with a variety of multisystemic features. Proximal muscle weakness, cataracts, thyroid disease and gallbladder diseases are more common in females than in males. A potential biomarker of the severity of muscle involvement includes muscle fat fraction derived from magnetic resonance imaging (MRI). However, the pattern of fat replacement and its relationships to clinical endpoints have not been studied in DM2. The objective of this study was to investigate the relationships of muscle fat fraction with motor performance (6-minute walk distance and 15-second step test) in female patients with DM2. We obtained lower extremity MRIs from eight female patients with DM2 using a T1W-Dixon protocol. To calculate muscle fat fractions, 15mm muscle volumes were segmented from the proximal, medial, and distal thighs and calves (**Figure 1A**). At each level, muscles were further subdivided into anterior, medial/lateral, and posterior (**Figure 1B**). The associations between muscle fat fraction and motor performance were calculated using Spearman's correlations (ρ). Mean age of the participants was 63 ± 11 years, and mean disease duration was 18 ± 11 years. Average muscle fat fraction at the thigh ($40.8 \pm 13.3\%$) was higher ($P=0.002$) than muscle fat fraction at the calf ($29.9 \pm 14.0\%$). The compartments with the highest fat fractions were the posterior thigh ($41.5 \pm 11.9\%$) and lateral calf ($31.4 \pm 8.2\%$) compartments. The muscle fat fraction of the thigh and calves was correlated with a 6-minute walk test ($\rho=-0.74$, $P=0.04$; $\rho=-0.71$, $P=0.05$) and step test ($\rho=-0.83$, $P=0.01$; $\rho=-0.86$, $P=0.007$). Our pilot data provide support that the measure of higher lower extremity muscle fat fraction is strongly correlated with worse motor performance in females with DM2. A longitudinal study is required to evaluate fat fraction as a biomarker of disease progression and therapeutic response in DM2.

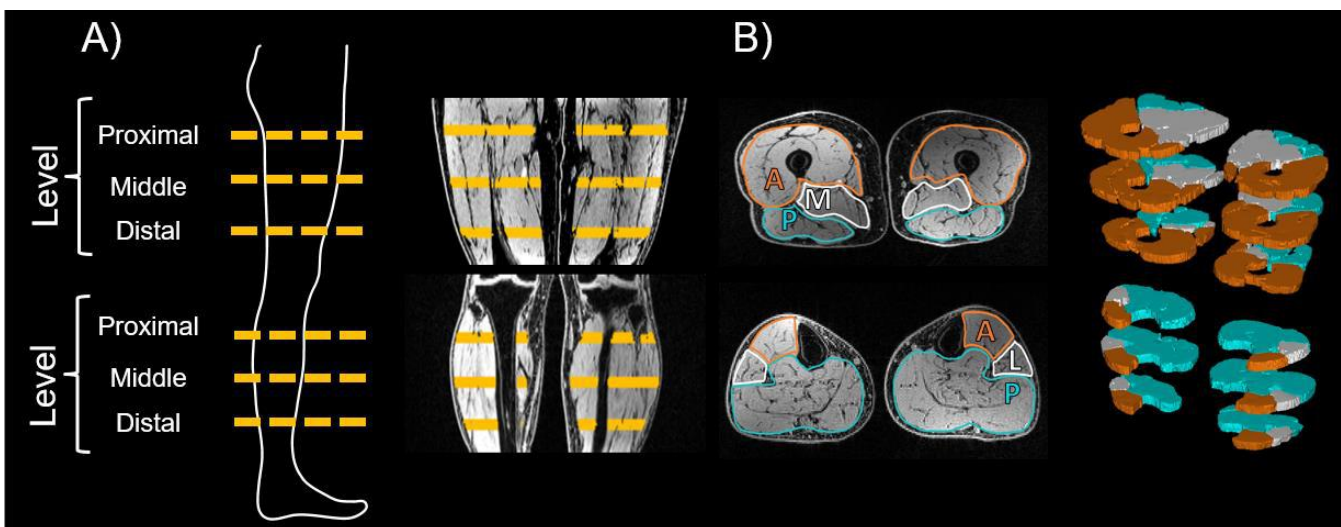


Figure 1. A) Positioning of analyzed muscle volumes. **B)** Muscle compartment delineation. Thigh compartments: anterior, medial, and posterior. Calf compartments: Anterior, lateral, and posterior.